



Pachyonychia Congenita Project

15 March 2005

Use of Articles in the Pachyonychia Congenita Bibliography

The articles in the PC Bibliography may be restricted by copyright laws. These have been made available to you by PC Project for the exclusive use in teaching, scholarship or research regarding Pachyonychia Congenita.

To the best of our understanding, in supplying this material to you we have followed the guidelines of Sec 107 regarding fair use of copyright materials. That section reads as follows:

Sec. 107. - Limitations on exclusive rights: Fair use

Notwithstanding the provisions of sections 106 and 106A, the fair use of a copyrighted work, including such use by reproduction in copies or phonorecords or by any other means specified by that section, for purposes such as criticism, comment, news reporting, **teaching (including multiple copies for classroom use), scholarship, or research**, is not an infringement of copyright. In determining whether the use made of a work in any particular case is a fair use the factors to be considered shall include - (1) the purpose and character of the use, including whether such use is of a commercial nature or is for nonprofit educational purposes; (2) the nature of the copyrighted work; (3) the amount and substantiality of the portion used in relation to the copyrighted work as a whole; and (4) the effect of the use upon the potential market for or value of the copyrighted work. The fact that a work is unpublished shall not itself bar a finding of fair use if such finding is made upon consideration of all the above factors.

We hope that making available the relevant information on Pachyonychia Congenita will be a means of furthering research to find effective therapies and a cure for PC.

Pachyonychia Congenita with Laryngeal Obstruction

Richard M. Haber, M.D., FRCPC*,[†] and Derek Drummond, M.D., FRCPS*,[†]

**Division of Dermatology, Department of Medicine, [†]Department of Otolaryngology,
University of Calgary, Calgary, AB, Canada*

Abstract: Pachyonychia congenita is a rare genodermatosis that can affect the larynx. Laryngeal obstruction is very unusual with only a few cases reported. A 2-year-old girl presented with typical clinical features of pachyonychia congenita shortly after birth. At age 9 months, following an upper respiratory infection, she developed stridor and hoarseness and was found to have severe laryngeal obstruction, which was felt to be secondary to pachyonychia congenita based on direct laryngoscopy and laryngeal biopsy. Leukokeratosis of her larynx was treated with CO₂ laser on three occasions, with improvement in her respiratory distress after each treatment. This report is the first case of pachyonychia congenita with laryngeal obstruction in which the gene mutation has been established (a deletional mutation in K6a), confirming that laryngeal obstruction can occur in PC-1.

Pachyonychia congenita (PC) is a rare autosomal dominantly inherited genodermatosis first described by Jadassohn and Lewandowski in 1906 (1). It is characterized by hypertrophic nail dystrophy, focal palmoplantar hyperkeratosis, follicular hyperkeratosis, and leukokeratosis of the oral mucosa (2). These clinical features are often present at birth or early infancy.

Pachyonychia congenita is caused by mutations in one of four keratin genes. PC-1 (Jadassohn–Lewandowski type) is caused by a mutation in K6a or K16 genes. PC-2 (Jackson–Lawler type) is caused by a mutation in K6b or K17 genes. Rarer tarda variants of PC-1 and PC-2 also exist in which the onset of the clinical features of PC develop later in life (3).

Traditionally both PC-1 and PC-2 show hypertrophic nail dystrophy as their most prominent feature as well as

focal palmoplantar keratoderma and follicular keratoses. Clinical differentiation of PC-1 from PC-2 has historically been suggested by more prominent oral leukokeratosis in PC-1, and by the presence of steatocystomas/pilosebaceous cysts, vellus hair cysts, hair abnormalities, and natal teeth in PC-2 (4). However, genotyping has shown that the degree of oral leukokeratosis can be quite variable in both PC-1 and PC-2, and pilosebaceous cysts can be seen in both types. Steatocystomas, vellus hair cysts, and natal teeth do appear to be specific clinical features seen in PC-2 (4).

Laryngeal involvement with leukokeratosis of the larynx is a lesser known manifestation of PC. It is likely more frequent than reported with the most common presentation being hoarseness. Hoarseness in association with PC was reported as early as 1935 (5). In a study of

Address correspondence to Richard M. Haber, M.D., FRCPC, Room 715, North Tower, Foothills Medical Centre, 1403–29th St. NW, Calgary, AB, Canada, or e-mail: Richard.haber@albertahealthservices.ca.

PC, patients from the International Pachyonychia Congenita Research Registry, hoarseness was reported in 16% of patients (4). In patients with known genotype, hoarseness occurred in both PC-1 and PC-2, with most having a mutation in K6a (4). Even more unusual is the occurrence of laryngeal obstruction in PC, a potentially life-threatening complication.

HISTORY

A 2-year-old girl presented with thickened fingernails (Fig. 1) and toenails as well as white areas on her tongue (Fig. 2) at the age of two days. Family history revealed a large pedigree of PC in her family (Fig. 3), including her mother, maternal grandfather, and her maternal great grandmother, who were all affected with PC. The index case of PC was the maternal great great grandmother. The young girl has an unaffected sister, and her father is also not affected.

The girl first developed stridor and hoarseness after an upper respiratory infection at the age of 9 months that was initially diagnosed as croup. However, her dyspnea and hoarseness did not clear, and she therefore under-

went direct laryngoscopy. The patient was found to have severe laryngeal narrowing, which was initially presumed to be secondary to laryngeal papillomas. She was referred to the University of Calgary and underwent repeat laryngoscopy, which showed whitish hyperkeratosis of her vocal cords with marked supraglottic laryngeal obstruction (Fig. 4). A laryngeal biopsy was obtained, which showed parakeratosis with plump superficial keratinocytes showing some irregularity of the nuclear membranes and cytoplasmic clearing. Scattered inflammatory cells were in the epidermis and the submucosa. In situ hybridization was negative for human papilloma virus. The clinical findings and pathology were felt to be compatible with laryngeal involvement secondary to her PC.

The girl was treated on two occasions, one month apart, with suspension laryngoscopy, and a CO₂ laser was used to remove the obstructing tissue in the larynx. These treatments relieved the laryngeal stenosis (Fig. 5), and her breathing clinically improved. At 3 years old, she

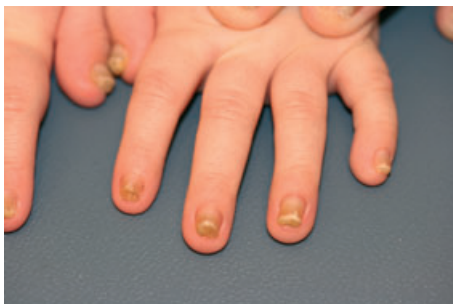

Figure 1. Thickening of all fingernails is seen in this 2-year-old girl.

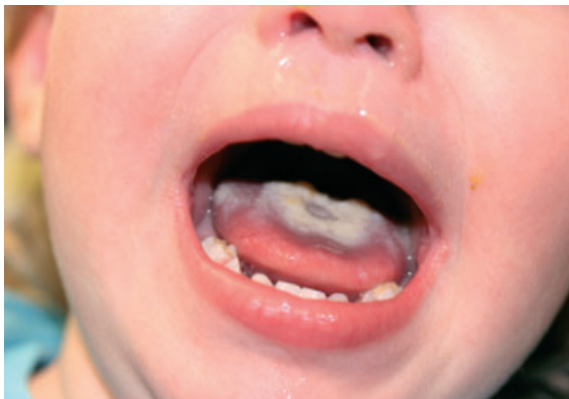

Figure 2. Leukokeratosis of the dorsum and side of the tongue is seen.

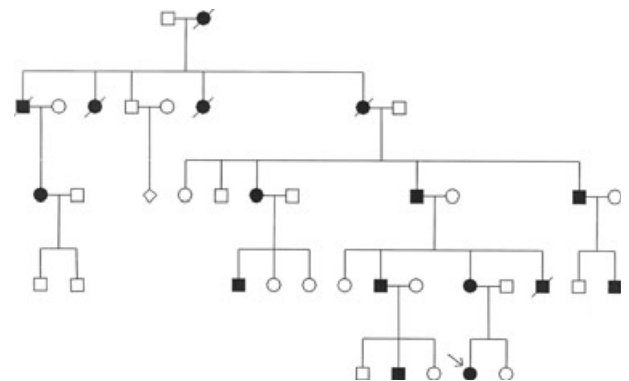


Figure 3. Pedigree showing affected family members (darkened circles and squares).

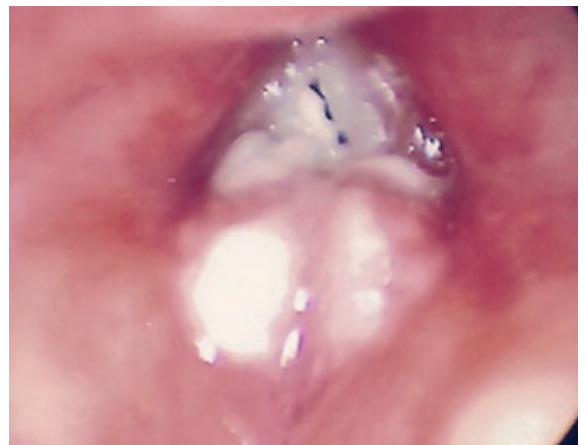


Figure 4. Leukokeratosis and stenosis of the larynx is seen at initial presentation with laryngeal obstruction.

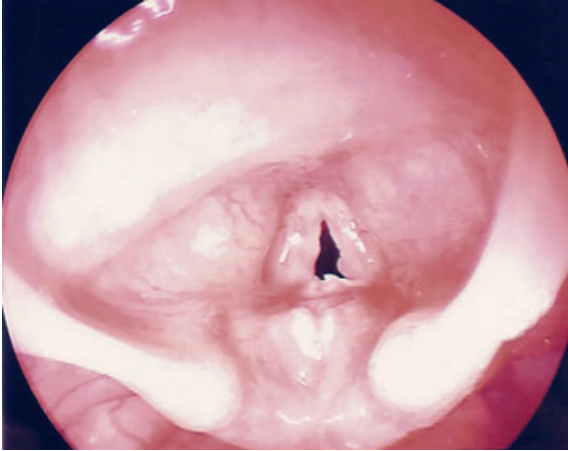


Figure 5. Marked improvement of laryngeal obstruction after first CO₂ laser treatment.

had recurrent stridor, although clinically less severe than her previous episodes, requiring one additional CO₂ laser treatment to a small area of leukokeratosis of the posterior glottic region. She responded well to this treatment and has had no further episodes of stridor since that time.

GENETIC STUDIES

Mutational analysis was performed on this young girl. This revealed an Asn172 deletion mutation in the KRT6a gene. This mutation is denoted as p.Asn172del (N172del). CAA was identified in exon 1 of the KRT6a gene resulting in the deletion of codon Asparagine 172. Mutations involving codon N172 (sometimes referred to as N171 depending on the numbering convention used) are the most common mutations associated with PC-1 and are felt to represent a mutation hotspot (6).

DISCUSSION

The first report of laryngeal obstruction in PC was by Cohn et al in 1976 (7). They reported a 3-year-old boy with PC who developed laryngeal obstruction following an upper respiratory infection. Direct laryngoscopy revealed multiple white exophytic lesions involving the ventricles, true cords, and subglottis. Biopsy of the laryngeal lesions showed thickening of the epithelium with acanthosis and parakeratosis. Intracellular vacuolization also occurred throughout the epithelium and a mild lymphocytic infiltrate in the subjacent connective tissue. The authors commented that the microscopic picture was identical to that previously described for PC involvement of oral and lingual mucosa (7,8).

This boy was treated with excision of the exophytic lesions using microlaryngeal techniques. Rapid improvement occurred in breathing and voice quality following

surgery. When he became hoarse again 7 months later, recurrent lesions on the larynx were again excised, and the patient became symptom free. His father was also said to have PC and hoarseness as a child, but he never experienced laryngeal obstruction. His hoarseness improved spontaneously over several years and never recurred.

The second report of laryngeal obstruction was in 1983 involving a 3-year-old boy from a large pedigree of PC (8). He developed rapid onset of respiratory distress requiring a tracheostomy. This boy was said to have three primary teeth at age 1 week, clinically suggesting he likely had PC-2, although the family was reported as PC-1 (Jadassohn–Lewandowski). This boy's father also had PC and required a tracheostomy in infancy. The family history included nine persons with severe recurrent upper respiratory symptoms requiring hospitalization as well as three infant deaths attributed to pneumonia. Five affected individuals had chronic hoarseness.

In 1987, Benjamin et al (9) reported a 15-year-old male diagnosed with PC, presenting with hoarseness and a laryngeal mass. He was treated initially with surgery and subsequently with laser. Although the clinical description of this boy was typical of PC, later mutational analysis showed no evidence of a keratin mutation but did show a mutation in the gene encoding connexin 30 (Personal communication Pachyonychia Congenita Project 2008) establishing this case as having Clouston Syndrome (hidrotic ectodermal dysplasia). Other reports exist in the literature confirming that Clouston Syndrome can clinically mimic PC (10), reinforcing the importance of establishing a definite diagnosis of PC by doing mutation analysis and finding a mutation in one of the four implicated keratin genes.

The most recent report of laryngeal obstruction in childhood PC was by Wudy et al (11) in 1995. They reported a 19-month-old girl with PC and chronic hoarseness. She developed inspiratory stridor around age 15 months, which was progressive. Upper respiratory infections exacerbated the hoarseness and stridor and led to respiratory distress. Direct laryngoscopy revealed bilateral leukoplakia involving the vocal cords and posterior commissure with an exophytic lesion on the left vocal cord. The exophytic white lesion on the left vocal cord was excised using microlaryngeal technique. Biopsy showed stratified squamous epithelium with parakeratosis and some vacuolated keratinocytes but no inflammatory cellular infiltrate. Postoperatively, the patient's stridor cleared, and the only residuum was slight persistent hoarseness.

The 3-year-old girl reported in this paper is only the fourth reported case in the literature of PC with laryngeal obstruction. This is the first case in which mutational

analysis was done, confirming the diagnosis of PC-1 and establishing that patients with PC-1 can develop laryngeal obstruction.

It is likely that patients with PC-2 could also develop laryngeal obstruction, as some patients who have hoarseness have been shown to have a mutation in K6b and K17 (4), establishing them as having PC-2. If laryngeal involvement can occur in patients with PC-2, it would be logical to expect these patients could also develop laryngeal obstruction if they had significant PC involvement of their larynx. However, no reports exist of documentation of laryngeal biopsy in which mutation analysis has been done to positively establish a diagnosis of PC-2. The case reported by Stieglitz, in which documentation of laryngeal involvement compatible with PC was done by direct laryngoscopy and biopsy, was likely a case of PC-2 in view of the history of perinatal teeth. However, mutational analysis was not available in 1983, and the type of PC cannot be positively established.

It is important for dermatologists and otolaryngologists to be aware that laryngeal involvement, and rarely laryngeal obstruction, can occur in patients with PC. Laryngeal obstruction is a potentially life-threatening complication in these patients. We feel that hoarseness in a child with PC should be examined by flexible laryngoscopy to rule out laryngeal involvement, and a biopsy should be done if suspicious lesions are identified.

Literature review of laryngeal obstruction in PC indicates that most cases have occurred at a young age (usually at 2–3 years of age) and often follow an upper respiratory infection. This seems logical as the larynx has a very small diameter at this age, and if affected by PC, inflammation from a concurrent infection could be enough to cause laryngeal obstruction.

The best treatment for laryngeal obstruction in patients with PC is not known. From the literature and this case report, it would appear that surgical excision or CO₂ laser vaporization of the PC leukokeratotic areas of the larynx can safely relieve the laryngeal obstruction, although treatments may need to be repeated if the patient relapses. It is known that keratins 6, 16, and 17 are stress response keratins and are rapidly induced on injury or inflammation (12). It is therefore theoretically possible that surgery or laser could actually make laryngeal obstruction worse if the trauma of these procedures stimulated the mutated keratin. If this is the case, the treatment of choice for patients with PC and laryngeal obstruction would be conservative therapy to allow the obstructed larynx to recover spontaneously. This has not been supported by

the few cases in the literature in which surgery or laser was successful.

Further cases of PC with laryngeal involvement or obstruction, where the diagnosis has been positively established with mutational analysis, need to be reported in the literature to know if laryngeal involvement or obstruction can occur in PC-2 as has been shown in this case with PC-1. Further case reports are necessary to determine if the treatment of choice in these unusual but life-threatening cases is aggressive surgery or laser therapy, or if these patients are best managed conservatively.

ACKNOWLEDGMENT

Mary Schwartz, director of the PC Project prepared the pedigree seen in Fig. 3.

REFERENCES

- Jadassohn J, Lewandowski F. Pachyonychia congenita: keratosis disseminata circumscripta (folliculosis). *Tylosmata. Leukokeratosis linguae* Berlin, Urban and Schwarzenberg, 29–31, 1906.
- Dahl PR, Daoud MS, Su WPD. Jadassohn-Lewandowski syndrome (pachyonychia congenita). *Semin Dermatol* 1995;14:129–134.
- Paller AS, Moore JA, Scher R. Pachyonychia congenita tarda: a late-onset form of pachyonychia congenita. *Arch Dermatol* 1991;127:701–703.
- Leachman SA, Kaspar RL, Fleckman P et al. Clinical and pathological features of Pachyonychia Congenita. *J Investig Dermatol Symp Proc* 2005;10:3–17.
- Kumer L, Loos H. *Über pachyonychia congenita* (Typus Riehl). *Wien Klin Wochenschr* 1935;48:174–179.
- Smith FJ, Liao H, Cassidy AJ et al. The genetic basis of pachyonychia congenita. *J Investig Dermatol Symp Proc* 2005;10:21–30.
- Cohn AM, McFarlane JR, Knox J. Pachyonychia congenita with involvement of the larynx. *Arch Otolaryngol* 1976;102:233–235.
- Stieglitz JB, Centerwall WR. Pachyonychia congenita (Jadassohn-Lewandowsky syndrome): a seventeen member, four-generation pedigree with unusual respiratory and dental involvement. *Am J Med Genet* 1983;14:21–28.
- Benjamin B, Parsons DS, Molloy HF. Pachyonychia with laryngeal involvement. *Int J Pediatr Otorhinolaryngol* 1987;13:205–209.
- van Steensel MAM, Jonkman MF, Van Geel M et al. Clouston syndrome can mimic pachyonychia congenita. *J Invest Dermatol* 2003;121:1035–1038.
- Wudy SA, Lenders H, Pirsig W et al. Diagnosis and management of laryngeal obstruction in childhood pachyonychia congenita. *Int J Pediatr Otorhinolaryngol* 1995;31:109–115.
- Lane EB, Mclean WHI. Keratins and skin disorders. *J Pathol* 2004;204:355–366.