



Pachyonychia Congenita Project

Use of Articles in the Pachyonychia Congenita Bibliography

The articles in the PC Bibliography may be restricted by copyright laws. These have been made available to you by PC Project for the exclusive use in teaching, scholarship or research regarding Pachyonychia Congenita.

To the best of our understanding, in supplying this material to you we have followed the guidelines of Sec 107 regarding fair use of copyright materials. That section reads as follows:

Sec. 107. - Limitations on exclusive rights: Fair use

Notwithstanding the provisions of sections 106 and 106A, the fair use of a copyrighted work, including such use by reproduction in copies or phonorecords or by any other means specified by that section, for purposes such as criticism, comment, news reporting, **teaching (including multiple copies for classroom use), scholarship, or research**, is not an infringement of copyright. In determining whether the use made of a work in any particular case is a fair use the factors to be considered shall include - (1) the purpose and character of the use, including whether such use is of a commercial nature or is for nonprofit educational purposes; (2) the nature of the copyrighted work; (3) the amount and substantiality of the portion used in relation to the copyrighted work as a whole; and (4) the effect of the use upon the potential market for or value of the copyrighted work. The fact that a work is unpublished shall not itself bar a finding of fair use if such finding is made upon consideration of all the above factors.

We hope that making available the relevant information on Pachyonychia Congenita will be a means of furthering research to find effective therapies and a cure for PC.

Novel mutation (p.L91P, c.272T>C) of keratin 17 in a case with pachyonychia congenita type 2

Dear Editor,

A 65-year-old Japanese woman visited our clinic with large cysts on the knees and buttocks. A dermatological examination revealed hypertrophic nail dystrophy of all fingernails and toenails, palmoplantar hyperkeratosis, and numerous cutaneous cysts over the trunk and limbs (Fig. 1a,b). Fungi were not identified in nails or palmoplantar lesions. Her teeth and tongue were normal. The family pedigree showed five affected persons over four generations (Fig. 1c). The 6-year-old grandson had moderate signs of nail hyperkeratosis, focal mild palmoplantar hyperkeratosis, and numerous milia over the trunk and limbs. He was born with natal teeth. We performed resection of her large cysts under general anesthesia. The histopathological diagnosis of all the cysts was epidermoid cyst. After obtained informed consent, blood samples obtained from the proband and her grandson were sent for genotyping and DNA was isolated using a standard procedure. The K6b and K17 genes were amplified by long-range polymerase chain reaction, using primers specific to the respective functional genes to avoid amplification of additional K6 genes or K17 pseudogenes. The primer pairs and conditions were as reported previously.¹ The amplified products were directly sequenced. A novel heterozygous mutation, p.L91P (c.272T>C) in the helix initiation motif of the *KRT17* gene was found in both the proband and her grandson (Fig. 1d). In 100 healthy controls, the mutation p.L91P was not detected. There had never been reported that the mutation p.L91P had conserved among different keratin molecules or that a similar mutation had been found in other keratin genes underlying other diseases.

Pachyonychia congenita (PC) is characterized by nail dystrophy, palmoplantar hyperkeratosis, hyperhidrosis, oral leukokeratosis and follicular keratosis. Its clinical classification into PC-1 and PC-2 is borne out genetically. The findings of PC-2 are similar to those of PC-1; however, palmoplantar keratoses in PC-2 are possibly less severe than in PC-1. Multiple epidermal cysts appearing after puberty, including both epidermoid cysts and steatocysts, are the best indicator of PC-2 in differentiation from PC-1. Point mutations in the K17 gene have been reported in association with PC-2.¹ K17 is constitutively expressed in the pilosebaceous unit and basal appendage keratinocytes, with lesser basal expression in palmoplantar skin and a number of other minor epithelial populations, but not in mucosa.² Mutations in the K6b isoform of keratin 6 also cause PC-2, suggesting this is the expression partner keratin of K17.³ However, there have been reported cases with overlapping clinical features of PC-1 and PC-2.⁴ Eliason *et al.* proposed a new classifica-

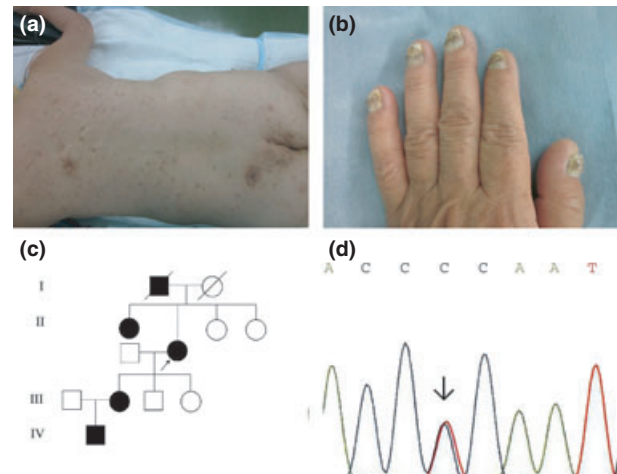


Figure 1. (a) Multiple cutaneous cysts located on the proband's back and buttocks. (b) The proband's nails showed severe dystrophy. (c) Pedigree of the PC-2 family, consistent with autosomal dominant inheritance. Arrow indicates the proband. (d) Direct DNA sequence analysis of the helix initiation motif in *KRT17*; the c. 272T>C transition mutation (p>Leu91Pro) was found in both the proband's and her grandson's blood.

tion system based on specific keratin mutations such as PC-6a, PC-6b, PC-16 and PC-17.⁵ Mutations in K17 can cause either PC-2 or a phenotype resembling familial steatocystoma multiplex with little or no nail changes.¹ Because great variation or heterogeneity in the phenotype of PC-2 has been reported, it is difficult to classify the clinical signs of PC-2. It is important to confirm the PC-2 phenotype by genotyping to differentiate PC-2 from other disorders with nail dystrophy and keratoderma. Further genetic studies are needed to clarify the pathogenesis of PC-2.

Makoto ICHIMIYA, Michiya YAMAGUCHI,
Kei NEMOTO, Masahiko MUTO

Department of Dermatology, Yamaguchi University Graduate School of
Medicine, Ube, Japan

REFERENCES

- Smith FG, Liao H, Cassidy AJ *et al.* The genetic basis of pachyonychia congenita. *J Invest Dermatol Symp Proc* 2005;**10**:21–30.
- McGowan KM, Coulombe PA. Keratin 17 expression in the hard epithelial context of the hair and nail, and its relevance for the pachyonychia congenita phenotype. *J Invest Dermatol* 2000;**114**:1101–1107.

- 3 Smith FJ, Jonkman MF, van Goor H *et al.* A mutation in human keratin K6b produces a phenocopy of the K17 disorder pachyonychia congenita type 2. *Hum Molec Genet* 1998;**7**:1143–1148.
- 4 Spaunhurst KM, Hogendorf AM, Smith FJD *et al.* Pachyonychia congenita patients with mutations in KRT6A have more extensive disease

compared with patients who have mutations in KRT16. *Br J Dermatol* 2012;**166**:875–878.

- 5 Eliason M, Leachman S, Feng B, Schwartz M, Hansen D. A review of the clinical phenotype of 254 patients with genetically confirmed pachyonychia congenita. *J Am Acad Dermatol* 2012;**67**:680–686.

Case of a Mongolian child with extensive Mongolian spots in mucopolysaccharidosis type VI: Identification of a novel mutation in the arylsulfatase B gene

Dear Editor,

Mucopolysaccharidoses (MPS) are a group of metabolic disorders caused by the malfunction of lysosomal enzymes needed to break down molecules called glycosaminoglycans. Previous studies have shown that patients with MPS, including Hurler syndrome (MPS I)¹ or Hunter syndrome (MPS II),² showed extensive Mongolian spots. Ochiai *et al.*³ argued that extensive Mongolian spots may lead to early diagnosis in patients with a mild form of Hunter syndrome. Here, we report a Mongolian boy with MPS type VI (Maroteaux–Lamy syndrome) who showed apparent clinical phenotypes of MPS including Mongolian spots.

The patient was a 7-year-old Mongolian boy. He had typical features such as coarse face, short stature, large belly with forward-curving spine, inguinal hernia, dysostosis multiplex, atrial septal defect and lung hypertension (Fig. 1a). In addition, he still had large Mongolian spots on his back (Fig. 1b,c). Although he was apparently having MPS because of his phenotype, the subtype was unclear. His elder sister had the same symptoms and died at the age of 8 years. Their parents were second cousins: thus, their coefficient of inbreeding equaled 1/64, enabling us to predict that the disease causing mutation carried by them should be homozygous (i.e. autozygous). Fortunately, his mental retardation was not recognized, suggesting his subtype might have been type VI because this is one of the subtypes of MPS without mental retardation. First, we analyzed his arylsulfatase B (*ARSB*) gene because it is a gene responsible for MPS VI. After obtaining informed consent from the patient and his mother, genomic DNA was extracted from their saliva samples by using Oragene DNA (DNA Genotek, Ottawa, ON, Canada). After amplification of exons 1–8 of the *ARSB* gene by polymerase chain reaction, the products were tested by single strand conformational polymorphism analysis in order to identify sequence variations. Finally, a novel homozygous missense mutation, c.278 C>T, p.P93L, was identified. The mutation newly identified in the patient was not found in 80 healthy individuals who were members of the same ethnic group. The missense mutation, p.P93L, involves a conserved

amino acid residue among all species carrying the *ARSB* ortholog, including the chimpanzee, horse, dog, mouse, chicken, zebra fish and frog. From these results, we genetically diagnosed him as having MPS VI.

Mucopolysaccharidosis VI is an autosomal recessive disorder caused by *ARSB* deficiency, which affects the storage of dermatan sulfate, resulting in a wide spectrum of clinical phenotypes, including coarse facial features, hydrocephalus, progressive skeletal deformity, kyphoscoliosis, respiratory difficulties, hernias, hearing loss and cardiac abnormalities. However, the mental development of the patients is often normal. In our case, clinical symptoms as well as extensive Mongolian spots were helpful for the diagnosis.

In Hunter syndrome, Ochiai *et al.*⁴ speculated that the metabolic abnormality may prevent the natural process of development, maturation and regression of melanocytes in Mongolian spots. We consider that this condition would be common in MPS VI. This case gives us a suggestion that the presence of extensive Mongolian spots may be a good and early marker for MPS.

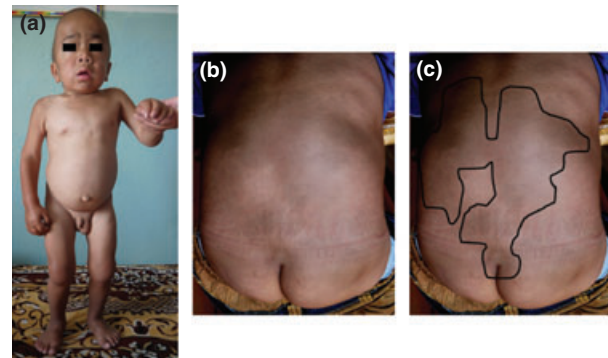


Figure 1. (a) Patient had a coarse face, short stature, large belly with forward-curving spine and inguinal hernia. (b,c) He still had large Mongolian spots on his back.