



Pachyonychia Congenita Project

15 March 2005

Use of Articles in the Pachyonychia Congenita Bibliography

The articles in the PC Bibliography may be restricted by copyright laws. These have been made available to you by PC Project for the exclusive use in teaching, scholarship or research regarding Pachyonychia Congenita.

To the best of our understanding, in supplying this material to you we have followed the guidelines of Sec 107 regarding fair use of copyright materials. That section reads as follows:

Sec. 107. - Limitations on exclusive rights: Fair use

Notwithstanding the provisions of sections 106 and 106A, the fair use of a copyrighted work, including such use by reproduction in copies or phonorecords or by any other means specified by that section, for purposes such as criticism, comment, news reporting, **teaching (including multiple copies for classroom use), scholarship, or research**, is not an infringement of copyright. In determining whether the use made of a work in any particular case is a fair use the factors to be considered shall include - (1) the purpose and character of the use, including whether such use is of a commercial nature or is for nonprofit educational purposes; (2) the nature of the copyrighted work; (3) the amount and substantiality of the portion used in relation to the copyrighted work as a whole; and (4) the effect of the use upon the potential market for or value of the copyrighted work. The fact that a work is unpublished shall not itself bar a finding of fair use if such finding is made upon consideration of all the above factors.

We hope that making available the relevant information on Pachyonychia Congenita will be a means of furthering research to find effective therapies and a cure for PC.

ONLINE FIRST

Paternal Germ Cell Mosaicism in Autosomal Dominant Pachyonychia Congenita

Lana N. Pho, MD; Frances J. D. Smith, PhD; David Konecki, MD; Sherri Bale, PhD; W. H. Irwin McLean, DSc, FRSE; Bernard Cohen, MD; Mark J. Eliason, MD; Sancy A. Leachman, MD, PhD

Background: Pachyonychia congenita (PC) is a genodermatosis caused by mutations in 1 of 4 known keratin genes, including *KRT6A*, *KRT6B*, *KRT16*, or *KRT17*. The most common mode of inheritance is autosomal dominant. Families with an affected parent are routinely counseled about the 50% transmission risk to each offspring. In some cases, families with a rare disorder like PC can initially present with an affected child while both parents are unaffected. This is usually the result of a spontaneous in utero mutation, and the risk of subsequent offspring being affected with the same condition is negligible (but may be increased above the general population's risk, although the exact risk is not currently known for PC).

Observations: We discuss a case of 2 affected children born to unaffected parents. We performed muta-

tional analyses of all 4 individuals in the family on DNA extracted from lymphocytes. Owing to the unusual presentation of 2 affected siblings, we also extracted DNA from the father's sperm cells for keratin gene mutational analysis. We describe the first case, to our knowledge, of germ cell mosaicism in PC.

Conclusion: Counseling of unaffected parents with a first child diagnosed as having PC should entail a discussion of the possibility of germ cell mosaicism contributing to an increased risk of having subsequent affected children.

Arch Dermatol.

Published online May 16, 2011.

doi:10.1001/archdermatol.2011.124

AUTOSOMAL DOMINANTLY inherited pachyonychia congenita (PC) is a rare, dominant negative keratin disorder that is associated with mutations in the genes for keratins 6a, 6b, 16, or 17. The most prominent manifestations of the condition include a painful, usually focal palmoplantar keratoderma, thickened nails, pilosebaceous cysts (including steatocystomas), oral leukokeratosis, follicular keratoses, and sometimes natal teeth.¹ Although the disorder seems to be completely penetrant, the spectrum and severity of disease manifestations in PC can vary considerably.¹

When the first child in an otherwise asymptomatic family is diagnosed as having PC, it is usually due to a spontaneous mutation that developed in utero.¹ However, it is also possible that the diagnosis could be missed in a parent with exceptionally mild disease symptoms, or that germ cell mosaicism exists in an asymptomatic parent. There are 3 possible mutational events that can occur in unaffected parents to produce an affected child. First, the keratin gene mutation can oc-

cur during development of the parental egg or sperm, or during early postfertilization before cellular differentiation into germ cells and somatic cells occurs (Figure 1A). This scenario results in an offspring who has both somatic cells and germ cells affected with the keratin gene mutation. The offspring is clinically affected with PC, and the offspring's children have a 50% risk of inheriting the same mutation. In the second scenario, illustrated in Figure 1B, the mutation occurs during early embryogenesis after differentiation of the cells into somatic and germ cells. In this case, the mutation developed in 1 of the somatic cells and *not* in germ cells (which are passed on to future generations). Because the offspring cannot transmit the affected PC gene to progeny, there is no increased risk to future pregnancies. The offspring may or may not exhibit a PC phenotype, depending on whether the *de novo* mutation affected cutaneous lineage cells. In skin diseases, this type of somatic mosaicism typically leads to a Blaschkoid pattern of involvement, as exemplified by cutaneous disorders such as segmental epidermal nevi, segmental

Author Affiliations:

Department of Dermatology, University of Utah, Salt Lake City (Drs Pho, Eliason, and Leachman); Epithelial Genetics Group, Division of Molecular Medicine, Colleges of Life Sciences and Medicine, Dentistry, & Nursing, University of Dundee, Dundee, Scotland (Drs Smith and McLean); GeneDx, Gaithersburg, Maryland (Drs Konecki and Bale); and Department of Dermatology, Johns Hopkins University, Baltimore, Maryland (Dr Cohen).

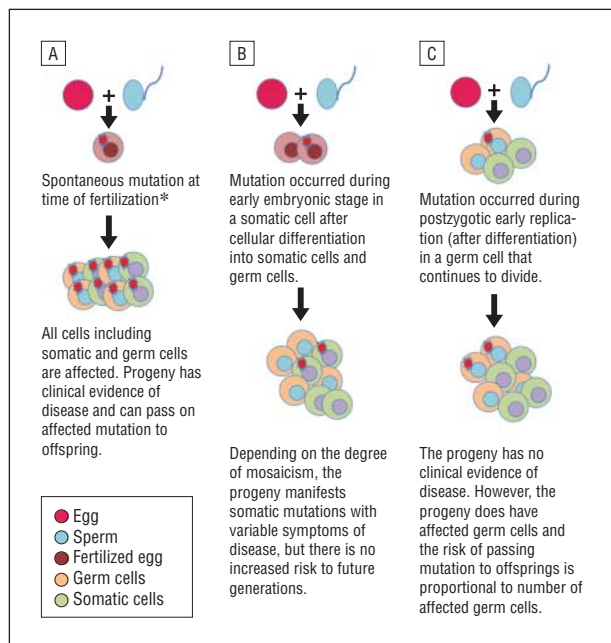


Figure 1. Schematic illustration of spontaneous mutations. Keratin gene mutations in both somatic and germ cells (A), somatic cells only (B), and germ cells only (C). *May occur at time of fertilization, or in an egg or sperm prior to fertilization.

Darier disease, and unilateral palmoplantar verrucous nevus.²⁻⁴ To our knowledge, no example of cutaneous mosaicism has yet been reported for PC. The third type of mutational event (Figure 1C) is the same as the previous scenario except the mutation arises in germ cells instead of somatic cells. This would result in a variable percentage of egg or sperm cells that carry the keratin mutation but would not result in a PC phenotype in that individual. Since the keratin mutation is limited to only the germ cells, the individual is asymptomatic, but the risk of transmitting the disease to future progeny is proportional to the number of affected germ cells. In summary, in utero mutations can develop only in somatic cells, only in germ cells, or in both cells. If an individual's germ cells are affected, the disease trait is transmitted to offspring; however, the individual will not have an observable phenotype unless his or her somatic cells are affected as well.

REPORT OF CASES

The affected female proband was noted to have thickened nails and oral leukokeratosis at birth and began developing plantar blistering around 18 months of age (Figure 2A). Mutation testing of DNA extracted from lymphocytes and buccal swab samples revealed a K6a (PC-1; OMIM 167200) N172del mutation, which is a 3-nucleotide (AAC) deletion (Figure 2A).⁵ A rigorously performed family history revealed no phenotypic features of PC in any family members, and thus additional family members were not offered genetic testing. When the mother became pregnant for a second time, she was told that it was very unlikely that the second child would have PC. However, when the second child was born, he

manifested nail discoloration and thickening similar to the characteristics in his sister (Figure 2B), and DNA mutation analysis on a buccal swab sample confirmed the same mutation seen in his older sibling (Figure 2B). The parents were counseled and consented to DNA mutation testing from buccal swab samples. Neither parent carried the same deleterious K6a mutation in the buccal mucosa (Figure 2C and D). However, sperm cells collected from the father revealed the presence of the K6a N172del mutation (Figure 2D). Thus, the father had a germ cell mosaicism that was transmittable to his children but not a somatic mutation leading to a clinical phenotype.

COMMENT

Herein we report for the first time, to our knowledge, an instructive case of 2 siblings shown to carry the same PC keratin gene mutation as a result of germ cell mosaicism. This case demonstrates the need for caution when counseling unaffected parents based on the first affected child in the family. There are several key points when counseling parents who have had a child with PC. First, the probability that subsequent offspring might be affected with the same condition ("recurrence risk") is based on obtaining a thorough family history and uncovering any mild phenotypic features in family members (especially in parents), since PC is known to be autosomal dominantly inherited. Performing genetic testing of clinically unaffected parents is not a standard of care owing to genetic testing costs, insurance coverage for unwarranted genetic testing, and the rarity of germ cell mosaicism in most diseases with a known mode of inheritance. Second, genetic counseling should address autosomal dominant inheritance and how wild-type and mutant alleles are passed to future offspring and manifest as phenotypic disease traits. In addition, pitfalls in the classic Mendelian modes of inheritance, including spontaneous mutations, germ cell mosaicism, and paternity issues, should be discussed.

Although there is a potential referral bias to a Web-based registry that favors identification of the first reported case in a family, the International Pachyonychia Congenita Research Registry (IPCRR) estimates that in approximately 64% of the cases (92 of 143 families), PC arises from a spontaneous mutation.⁵ In most cases in which no phenotypic risk factors for PC are identified in the parents, the PC in the child most likely resulted from a very early in utero spontaneous mutation and not from a germ cell mosaicism, as demonstrated in our case report. Mutation testing was not performed in the parents from these families for reasons discussed in the previous section. However, none of these families showed multiple affected siblings from unaffected parents. A limitation in this observation is that many families have chosen to have too small a family size to reasonably conclude whether germ cell mosaicism is present. Even if germ cell mosaicism occurred in such a small family unit, only 50% of offspring would be affected, and disease recurrence might still not be observed.

Germ cell mosaicism has been reported in other genodermatoses, including neurofibromatosis type 1, dystro-

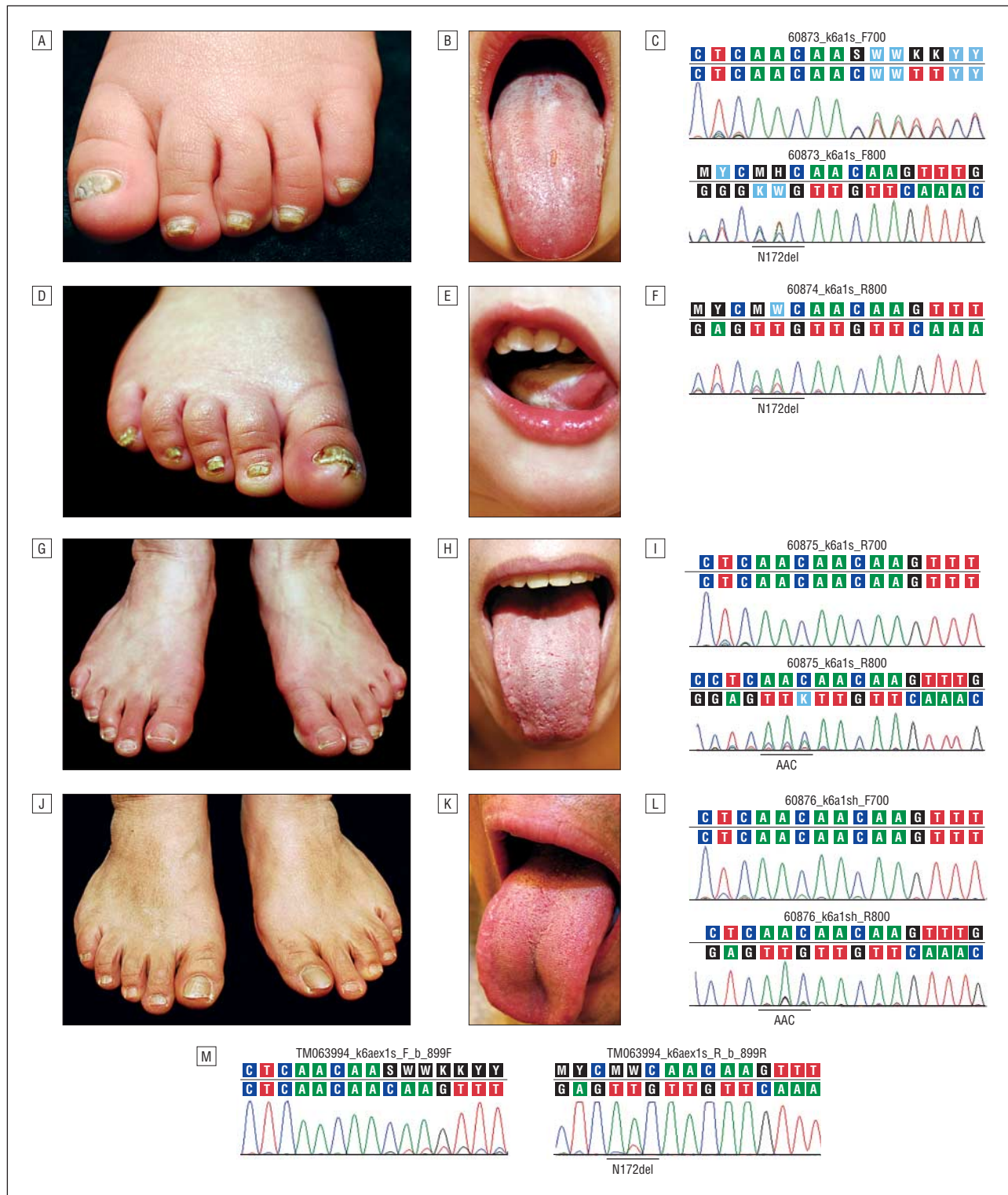


Figure 2. Two affected siblings have similar phenotypic features, and their parents are clinically unaffected. Photographs of the female proband's foot (A) and mouth (B) and corresponding mutation analysis on DNA extracted from buccal mucosa showing K6a N172del mutation, which is a 3-nucleotide (AAC) deletion (C). Photographs of the affected brother's foot (D) and mouth (E) and corresponding mutation analysis on DNA extracted from buccal mucosa showing the K6a N172del mutation, which is a 3-nucleotide (AAC) deletion (F). Photographs of the unaffected mother's feet (G) and mouth (H) and corresponding mutation analysis on DNA extracted from buccal mucosa showing no deletion of nucleotides AAC (I). Photographs of the unaffected father's feet (J) and mouth (K) and corresponding mutation analysis on DNA extracted from buccal mucosa showing no deletion of nucleotides AAC (L). However, DNA extracted from sperm shows the K6a N172del mutation, which is a 3-nucleotide (AAC) deletion similar to the DNA analysis from buccal mucosa of affected children (M).

phic epidermolysis bullosa, and epidermolytic hyperkeratosis.^{6,7} Previous studies of autosomal and X-linked chromosome diseases with evidence of germ cell mosa-

icism revealed that up to 50% of carriers also have mutations in somatic cells.⁸ Thus, uncovering an apparent spontaneous mutation case in an otherwise asymptomatic family

can often lead to diagnosis in a mildly symptomatic parent. It is important to note that patients with a mosaic manifestation of disease (eg, a patient with Blaschkoid Darier disease) should be warned of the possibility of germ cell involvement and the possibility of transmitting a more severe (generalized) manifestation of the disorder to offspring.³

One relatively common explanation for observing 2 affected children with unaffected parents is autosomal recessive inheritance. Two previous case reports described an autosomal recessive form of PC,^{9,10} but these case reports describing this mode of inheritance are not substantiated by confirmed molecular diagnosis. The IPCRR has now enrolled 253 individuals with genetically confirmed PC mutations belonging to a total of 143 families, and there is currently not a single case in which PC keratin mutations have demonstrated a recessive pattern of inheritance. Taken together, these data suggest that a recessive form of PC has not yet been identified, and parents should be counseled accordingly.

The main lesson to be learned in the present case is that although germ cell mosaicism is rare, it can be a cause of a second affected child born to otherwise asymptomatic parents. Counseling of clinically unaffected parents with an affected child should include mention of recurrence risk, including the very rare possibility of germ cell mosaicism. Recurrence risk of germ cell mosaicism in specific and well studied autosomal dominant inherited diseases ranges from 6% to 30% (presumably depending on the percentage of germ cells affected with the mutation), but PC-specific rates will become available only as mutation testing is applied to cases similar to the family described herein.^{8,11}

In summary, we describe the first case of germ cell mosaicism in Pachyonychia congenita. Germ cell mosaicism is rarely encountered in clinical practice, and the rates of occurrence vary among different disorders.⁸ Indeed, it is only identified when a child with disease resulting from presumed spontaneous mutation has a sibling who presents with disease symptoms and has an identical mutation. The parents' egg or sperm cells are rarely tested because of the difficulty of obtaining specimens for evaluation, especially ovarian cells, and the fear of precipitating parental disputes or paternity concerns. As genetic testing for inherited cutaneous syndromes becomes more readily accessible and is used more frequently, it is important to develop counseling strategies that incorporate genetic risks including traditional Mendelian inheritance, spontaneous mutation rate, germ cell mosaicism, and paternal identity.

Accepted for Publication: March 22, 2011.

Published Online: May 16, 2011. doi:10.1001/archdermatol.2011.124

Correspondence: Sancy A. Leachman, MD, PhD, Department of Dermatology, University of Utah School of Medicine, 30 N 1900 E, Ste 4A330, Salt Lake City, UT 84132 (Sancy.Leachman@hci.utah.edu)

Author Contributions: Drs Pho, Smith, Bale, Konecki, Eliason, and Leachman had full access to all of the data in the study and take responsibility for the integrity of the data and the accuracy of the data analysis. *Study concept and design:* Smith, McLean, Cohen, and Leachman. *Acquisition of data:* Pho, Konecki, Bale, and Eliason, and Leachman. *Analysis and interpretation of data:* Smith, Konecki, Bale, McLean, and Leachman. *Drafting of the manuscript:* Pho, Smith, and Leachman. *Critical revision of the manuscript for important intellectual content:* Pho, Smith, Bale, and Leachman. *Statistical analysis:* Leachman. *Obtained funding:* Leachman. *Administrative, technical, and material support:* Pho, Konecki, Bale, and Leachman. *Study supervision:* Pho and Leachman.

Financial Disclosure: Drs Konecki and Bale are employed by GeneDx and performed the mutational analyses.

Funding/Support: This study was supported by grants to Drs Pho and Leachman from the Pachyonychia Congenita (PC) Project (Salt Lake City, Utah; www.pachyonychia.org) and the Huntsman Cancer Foundation, and a grant to Dr Leachman from the Tom C. Mathews Jr Familial Melanoma Research Clinic. Dr Smith received funding from the PC Project to perform the initial mutation analysis.

Role of the Sponsors: The sponsors had no role in the design and conduct of the study; in the collection, analysis, and interpretation of data; or in the preparation, review, or approval of the manuscript.

Additional Contributions: We are grateful for the generous support, collegiality, and useful suggestions from members of PC Project, as well as the IPCC. Most of all, we would like to thank the patients with PC who have offered their unwavering support.

REFERENCES

1. Leachman SA, Kaspar RL, Fleckman P, et al. Clinical and pathological features of pachyonychia congenita. *J Invest Dermatol Symp Proc.* 2005;10(1):3-17.
2. Paller AS, Syder AJ, Chan YM, et al. Genetic and clinical mosaicism in a type of epidermal nevus. *N Engl J Med.* 1994;331(21):1408-1415.
3. Sakuntabhai A, Dhitavat J, Burge S, Hovnanian A. Mosaicism for ATP2A2 mutations causes segmental Darier's disease. *J Invest Dermatol.* 2000;115(6):1144-1147.
4. Terrinoni A, Puddu P, Didona B, et al. A mutation in the V1 domain of K16 is responsible for unilateral palmoplantar verrucous nevus. *J Invest Dermatol.* 2000;114(6):1136-1140.
5. Smith FJ, Liao H, Cassidy AJ, et al. The genetic basis of pachyonychia congenita. *J Invest Dermatol Symp Proc.* 2005;10(1):21-30.
6. Consoli C, Moss C, Green S, Balderson D, Cooper DN, Upadhyaya M. Gonosomal mosaicism for a nonsense mutation (R1947X) in the *NF1* gene in segmental neurofibromatosis type 1. *J Invest Dermatol.* 2005;125(3):463-466.
7. Cserhalmi-Friedman PB, Garzon MC, Guzman E, et al. Maternal germline mosaicism in dominant dystrophic epidermolysis bullosa. *J Invest Dermatol.* 2001;117(5):1327-1328.
8. Zlotogora J. Germ line mosaicism. *Hum Genet.* 1998;102(4):381-386.
9. Giustini S, Amorosi B, Canci C, et al. Pachyonychia congenita with steatocystoma multiplex: a report of two cases and a discussion of the classification. *Eur J Dermatol.* 1998;8(3):158-160.
10. Chong-Hai T, Rajagopalan K. Pachyonychia congenita with recessive inheritance. *Arch Dermatol.* 1977;113(5):685-686.
11. Mettler G, Fraser FC. Recurrence risk for sibs of children with "sporadic" achondroplasia. *Am J Med Genet.* 2000;90(3):250-251.