



Pachyonychia Congenita Project

Use of Articles in the Pachyonychia Congenita Bibliography

The articles in the PC Bibliography may be restricted by copyright laws. These have been made available to you by PC Project for the exclusive use in teaching, scholarship or research regarding Pachyonychia Congenita.

To the best of our understanding, in supplying this material to you we have followed the guidelines of Sec 107 regarding fair use of copyright materials. That section reads as follows:

Sec. 107. - Limitations on exclusive rights: Fair use

Notwithstanding the provisions of sections 106 and 106A, the fair use of a copyrighted work, including such use by reproduction in copies or phonorecords or by any other means specified by that section, for purposes such as criticism, comment, news reporting, **teaching (including multiple copies for classroom use), scholarship, or research**, is not an infringement of copyright. In determining whether the use made of a work in any particular case is a fair use the factors to be considered shall include - (1) the purpose and character of the use, including whether such use is of a commercial nature or is for nonprofit educational purposes; (2) the nature of the copyrighted work; (3) the amount and substantiality of the portion used in relation to the copyrighted work as a whole; and (4) the effect of the use upon the potential market for or value of the copyrighted work. The fact that a work is unpublished shall not itself bar a finding of fair use if such finding is made upon consideration of all the above factors.

We hope that making available the relevant information on Pachyonychia Congenita will be a means of furthering research to find effective therapies and a cure for PC.

LETTER TO THE EDITOR

Impaired wound healing and cheilitis in a Pachyonychia Congenita K6a family

Editor

Pachyonychia Congenita (PC) is a rare autosomal dominant keratinization disorder, where the majority of disease causing mutations has been detected in the keratin genes *KRT6A/B*, *KRT16* and *KRT17*.^{1–3} These mutations lead to extreme fragility of the cells where mutated keratins are expressed.³ Phenotypic manifestations include palmoplantar keratoderma; hypertrophic nail dystrophy; oral leukokeratosis and cyst formation arising from pilosebaceous hyperkeratosis. Variation in manifestation of these symptoms has been described. A suggested genetic modifier (in a PC-K16 family) is concomitant mutations in the *FLG* gene, leading to loss-of-function of the epidermal filament aggregating protein (filaggrin).⁴ We encountered a PC-K6a family, with a missense c.1385T>A in *KRT6A*.⁵ The seven living affected individuals in the family took part in a standardized interview and were examined by a dermatologist. To rule out prevalent *FLG* mutations in this family, the *FLG* gene was analysed for variants *R501X*, *2282del4*, *S3247X* and *R2447X* as described previously.⁶ No mutations were detected in any patients. All family members had oral leukokeratosis, dystrophic nails and follicular hyperkeratosis (Fig. 1). All affected members but V:1 suffered from persistent cheilitis (perilabial scaling, fissures, erosions or crusts)

and impaired wound healing were reported from III:1, IV:4, IV:5 (Table 1). Three family members reported such muscle pain and slow wound healing that they could not work, and prevented the affected boy from participating in school gymnastics.

We previously detected a missense mutation in *KRT6A* (c.1385T>A) causative for PC in this family. There was clear phenotypic variation among affected family members and several individuals reported symptoms impaired wound healing and cheilitis, neither commonly associated with PC. Although not objectively quantified, health care professionals also spontaneously commented on delayed wound closure. It has recently been demonstrated that type II keratins (K6a/K6b) as well as type I keratins (K16/K17) are rapidly induced in wound-proximal epidermal keratinocytes after skin injury and in chronic disease settings (e.g. psoriasis, cancer).⁷ However, skin grafting experiments have showed that *KRT6^{-/-}* keratinocytes are mechanically compromised and readily rupture while attempting to migrate into the setting of acute skin wounds *in situ*.⁸ Furthermore, *KRT6A^{-/-}* mice display impaired re-epithelialization of superficial wounds.⁹ Taking our findings into consideration, *KRT6A* mutations may predispose to delayed wound healing in certain individuals. This phenotype may be underreported due to difficulties in objectively assessing delayed wound healing; however, a larger patient material is needed to determine how common these symptoms are among PC patients or if these findings are family specific.

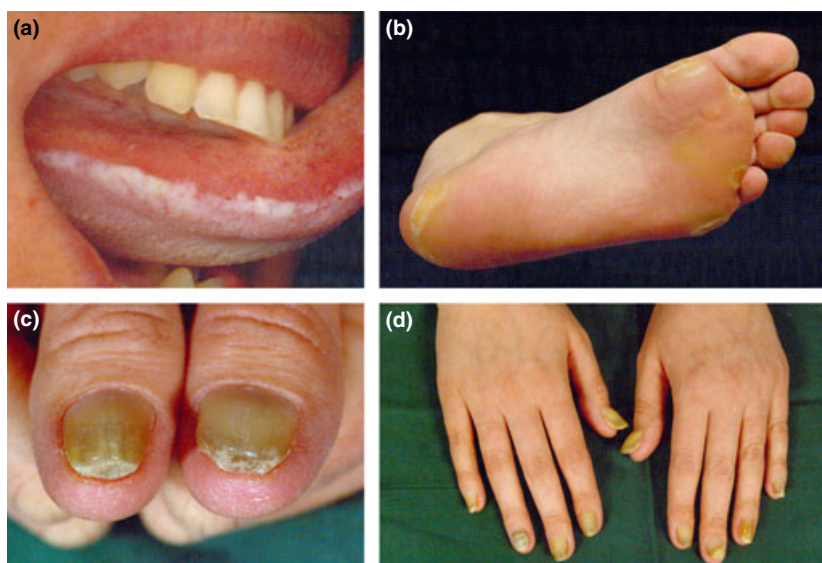


Figure 1 Common manifestations in the affected PC-K6a family. Symptoms include oral leukoplakia (a), plantar keratoderma (b) and nail dystrophy (c,d).

Table 1 Phenotype comparison within the family. No pilosebaceous cysts, teeth at birth or pilo torti were observed

Individual	III:1	III:2	IV:4	IV:5	IV:6	V:1	V:2
Age	68	67	40	33	42	0.5	11
Sex	F	M	F	F	F	F	M
Oral leucokeratosis	+	+	+	+	+	+	+
Follicular hyperkeratosis	+	+	+	+	+	+	+
Dystrophic nails	+	+	+	+	+	+	+
Palmoplantar keratodermi	+	+	+	+	+	–	+
Cheilitis	+	+	+	+	+	+	+
Severe muscle pain	+	–	+	+	+	+	–
Impaired wound healing	+	–	+	+	–	+	–
<i>FLG</i> mutation (R501X, 2282del4, S3247X, R2447X)	–	–	–	–	–	–	–
<i>KRT6A</i> mutation (c.1385T>A)	+	+	+	+	+	+	+

As a previously reported genetic disease modifier in PC-K16 is *FLG* mutation R2447X,⁴ we ruled out prevalent *FLG* mutations in this family. Keratin–filaggrin interactions occur during late epidermal differentiation, and disruption of this pathway could contribute to a severe phenotype in individuals with concomitant *KRT16* and *FLG* mutations.⁴ However, PC-K6a and PC-K16 have besides different causative genes also phenotypic differences. PC-K6a may have earlier onset, more extensive nail disease and more substantial disease outside palms and soles, compared with PC-K16.¹⁰ Taking genotypic and phenotypic differences into account between these two types, we cannot exclude that *FLG*'s role as a disease modifier in PC is confined to patients carrying *KRT16* mutations. However, other disease modifying genetic (and/or environmental) factors could also interact with pathways relevant for PC pathogenesis, such as cytoskeleton assembly and function.

In conclusion, we here describe a family with PC-K6a, manifesting atypical symptoms of impaired wound healing and cheilitis. We could not confirm *FLG* mutations as a disease modifier in this family. Hence, it is likely that other genetic or environmental disease modifiers are involved in the variable phenotypic expression of the disorder, including the novel symptoms reported here.

Acknowledgements

The authors would like to thank the participating family.

M.C.G. Winge,^{1,2,*} M. Bradley,^{1,2,†} E. Björck¹

¹Department of Molecular Medicine and Surgery, Center for Molecular Medicine L8:02, Karolinska Institutet, ²Department of Medicine Solna, Karolinska Institutet, Stockholm, Sweden

*Correspondence: M.C.G. Winge. E-mail: marten.winge@ki.se

†The authors contributed equally to this work.

References

- Bowden PE, Haley JL, Kansky A, Rothnagel JA, Jones DO, Turner RJ. Mutation of a type II keratin gene (K6a) in pachyonychia congenita. *Nat Genet* 1995; **10**: 363–365.
- McLean WH, Rugg EL, Lunny DP *et al*. Keratin 16 and keratin 17 mutations cause pachyonychia congenita. *Nat Genet* 1995; **9**: 273–278.
- McLean WH, Hansen CD, Eliason MJ, Smith FJ. The phenotypic and molecular genetic features of pachyonychia congenita. *J Invest Dermatol* 2011; **131**: 1015–1017.
- Gruber R, Wilson NJ, Smith FJ *et al*. Increased pachyonychia congenita severity in patients with concurrent keratin and filaggrin mutations. *Br J Dermatol* 2009; **161**: 1391–1395.
- Smith FJ, Liao H, Cassidy AJ *et al*. The genetic basis of pachyonychia congenita. *The journal of Investigative Dermatology Symposium Proceedings/The Society for Investigative Dermatology, Inc [and] European Society for Dermatological Research* 2005; **10**: 21–30.
- Sandilands A, Terron-Kwiatkowski A, Hull PR *et al*. Comprehensive analysis of the gene encoding filaggrin uncovers prevalent and rare mutations in ichthyosis vulgaris and atopic eczema. *Nat Genet* 2007; **39**: 650–654.
- Rotty JD, Coulombe PA. A wound-induced keratin inhibits Src activity during keratinocyte migration and tissue repair. *J Cell Biol* 2012; **197**: 381–389. PubMed PMID: 22529101. Pubmed Central PMCID: 3341159.
- Wong P, Coulombe PA. Loss of keratin 6 (K6) proteins reveals a function for intermediate filaments during wound repair. *J Cell Biol* 2003; **163**: 327–337. PubMed PMID: 14568992. Pubmed Central PMCID: 2173512.
- Wojcik SM, Bundman DS, Roop DR. Delayed wound healing in keratin 6a knockout mice. *Mol Cell Biol* 2000; **20**: 5248–5255. PubMed PMID: 10866680. Pubmed Central PMCID: 85973.
- Spaunhurst KM, Hogendorf AM, Smith FJ *et al*. Pachyonychia congenita patients with mutations in *KRT6A* have more extensive disease compared with patients who have mutations in *KRT16*. *Br J Dermatol* 2012; **166**: 875–878.

DOI: 10.1111/jdv.12386